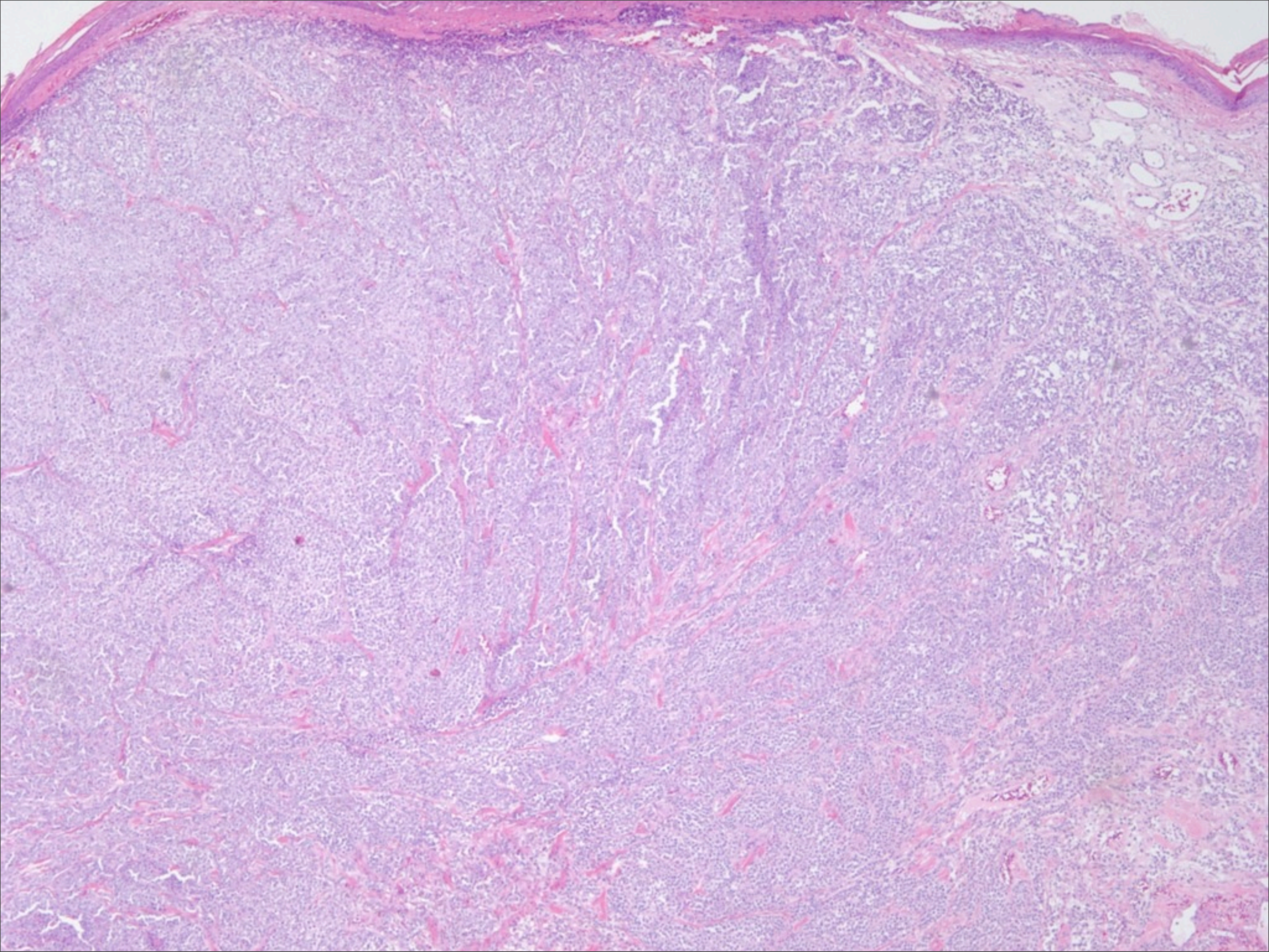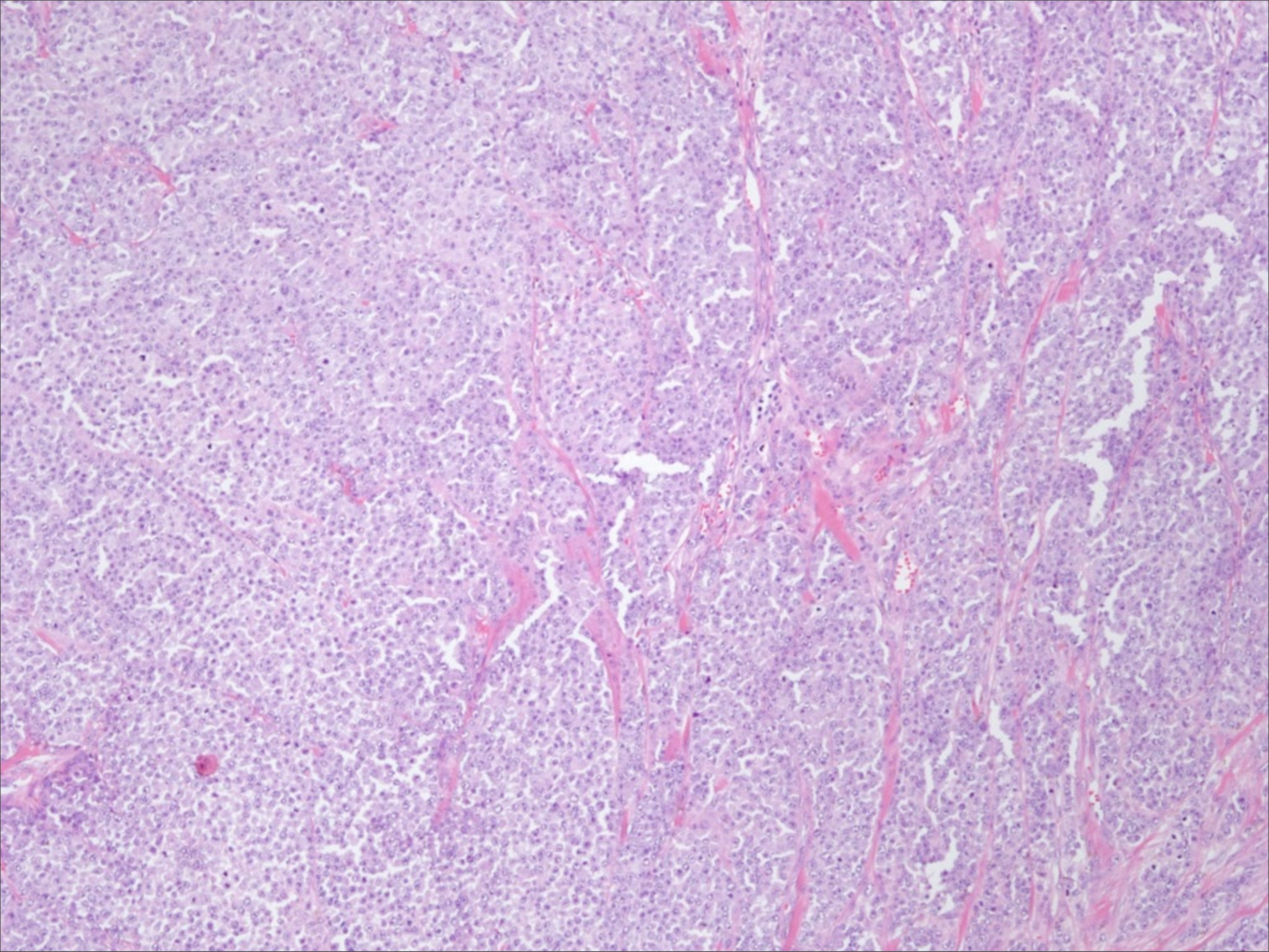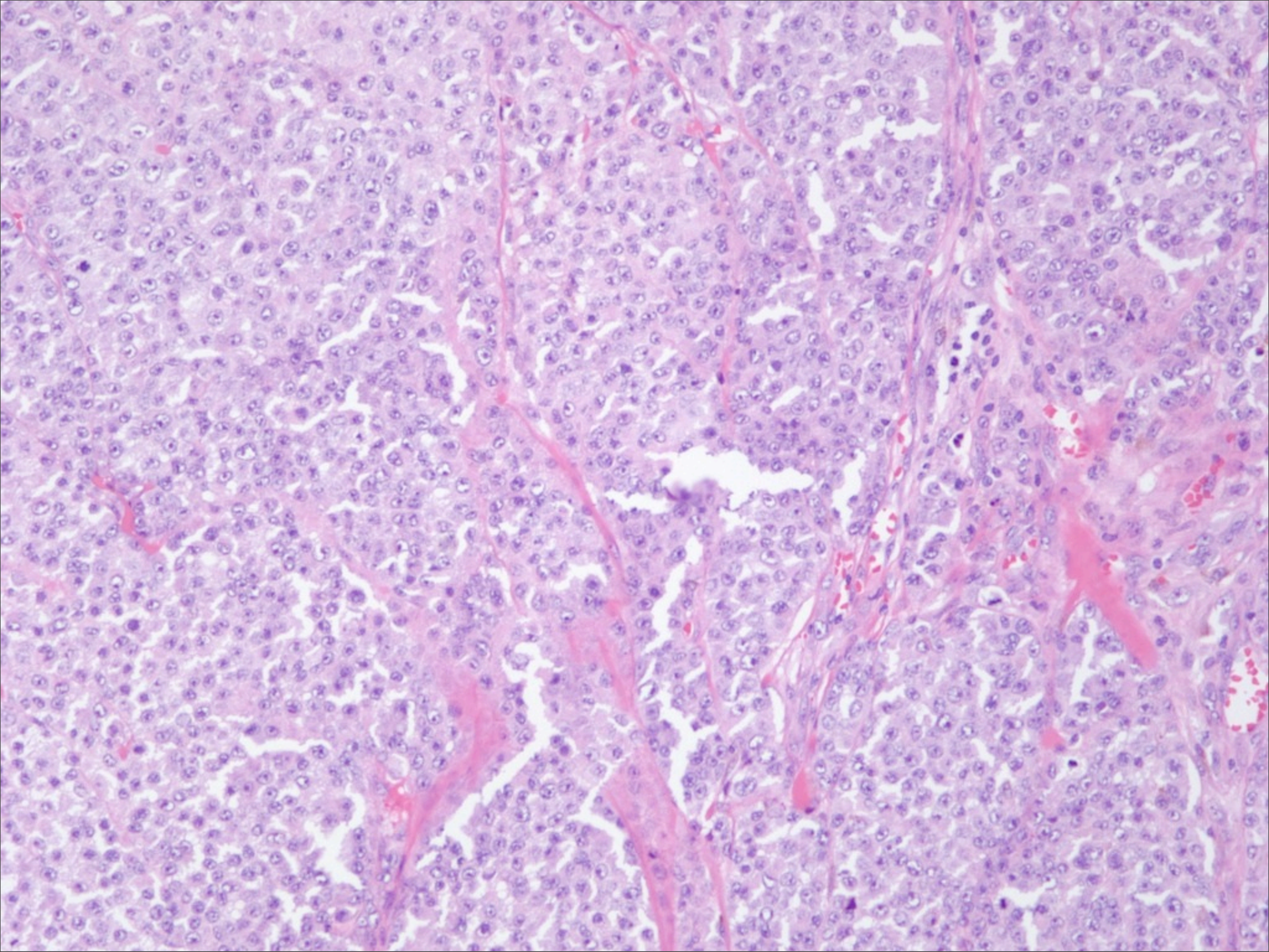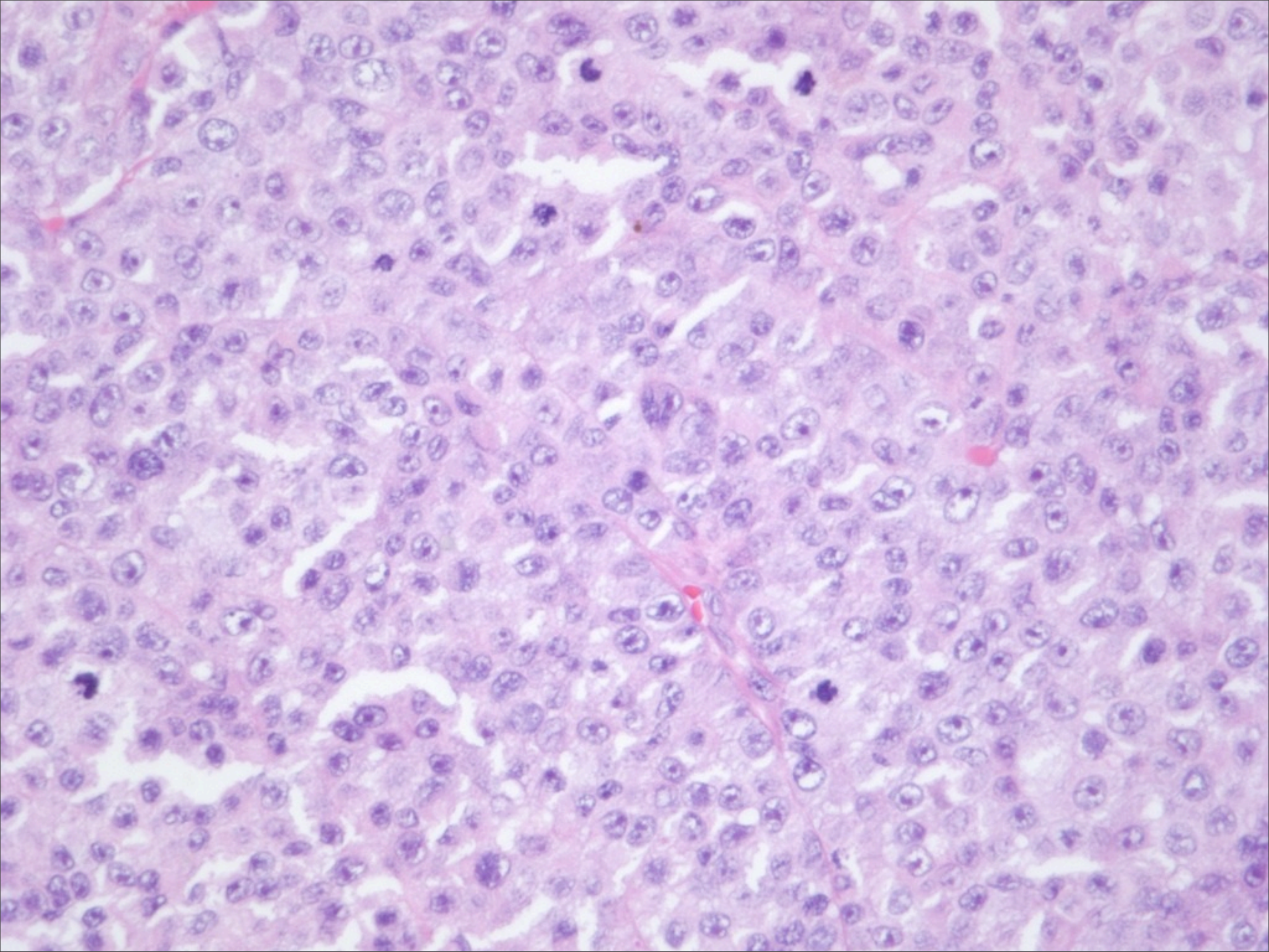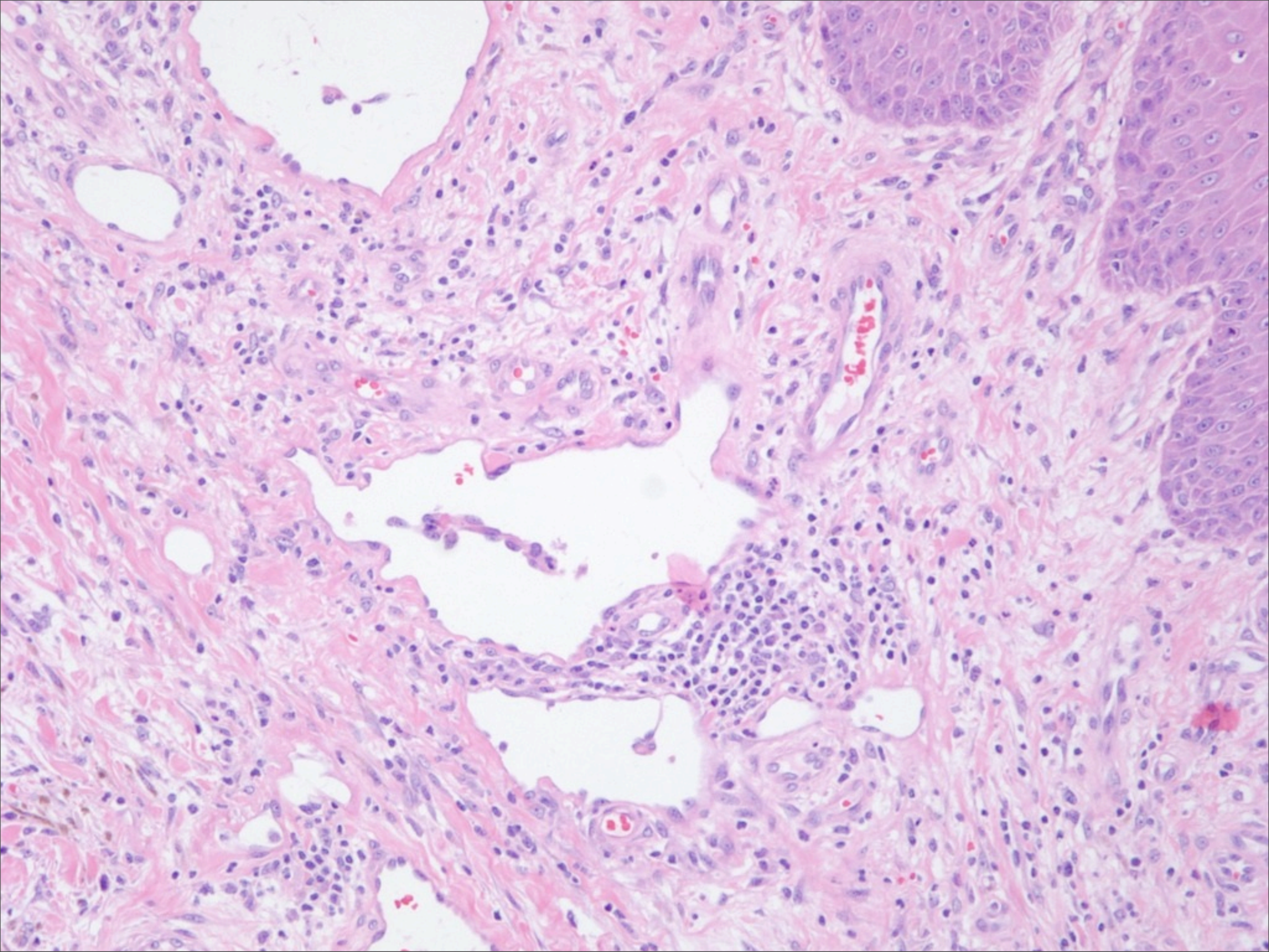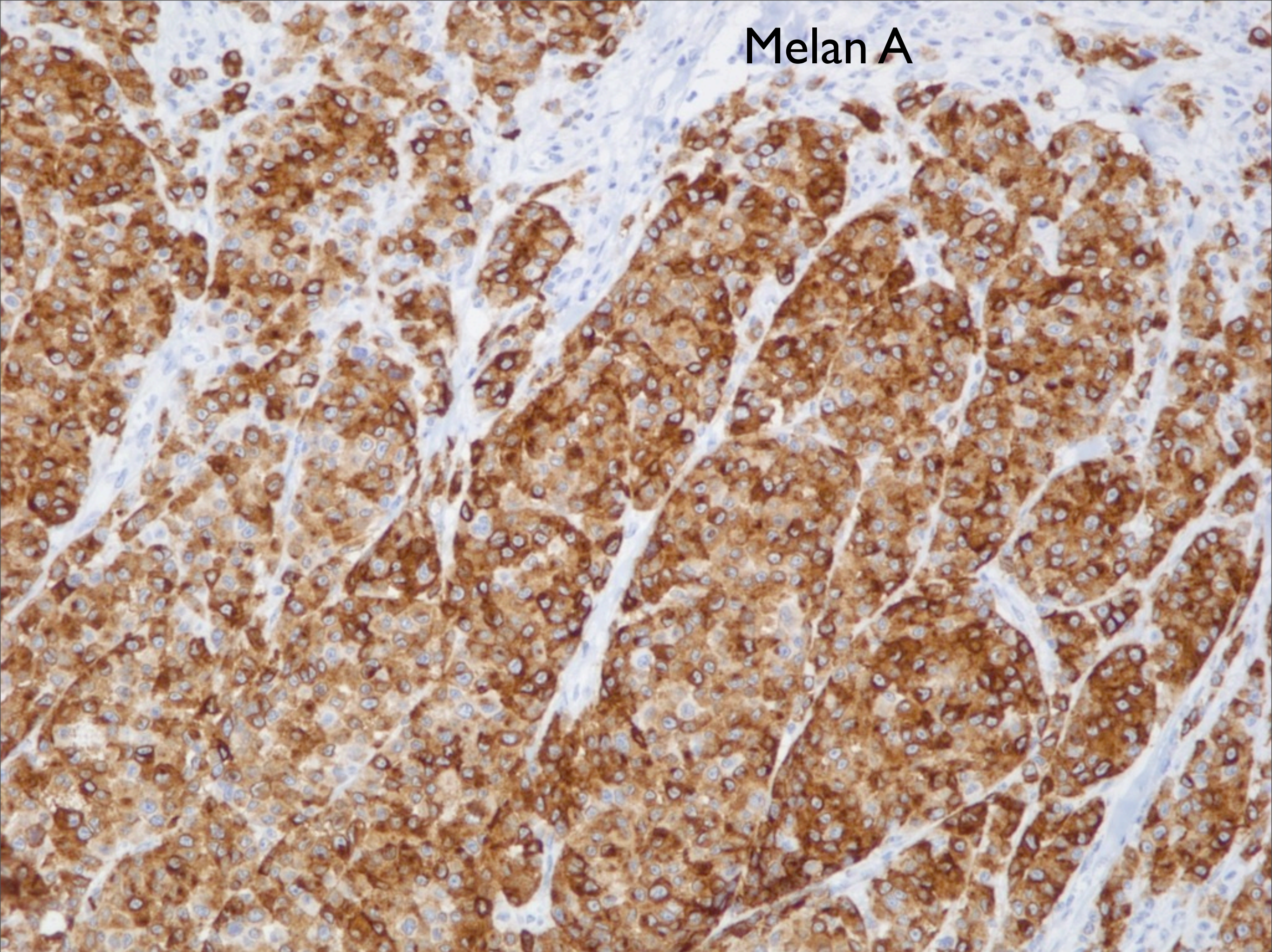
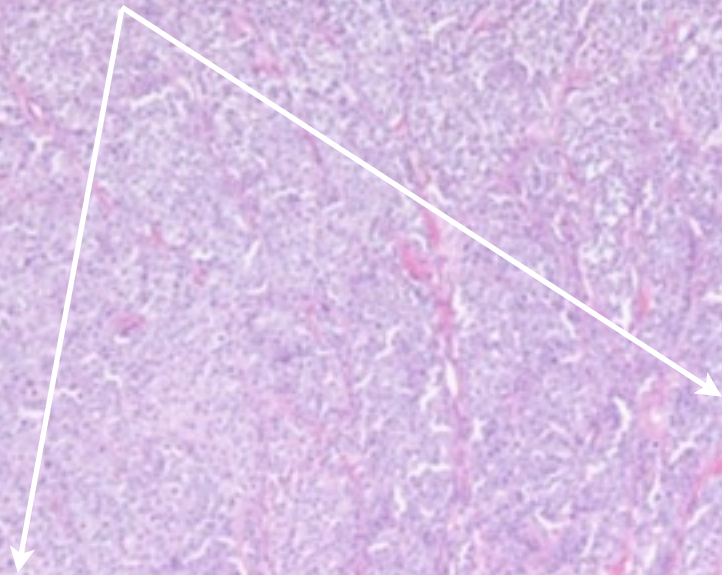


Melan A



Malignant Melanoma Amelanotic Type with Lymphovascular Invasion

Diffuse sheets of pleomorphic cells



Confirm with IHC